

Review

The inflammatory process of gout and its treatmentBruce N Cronstein¹ and Robert Terkeltaub²¹Department of Medicine and Division of Clinical Pharmacology, New York University School of Medicine, New York, New York, USA²San Diego VAMC Rheumatology Section and University of California, San Diego, California, USACorresponding author: Bruce N Cronstein, Bruce.Cronstein@nyumc.org

Published: 12 April 2006

This article is online at <http://arthritis-research.com/content/8/S1/S3>

© 2006 BioMed Central Ltd

Arthritis Research & Therapy 2006, **8(Suppl 1):S3**

(doi:10.1186/ar1908)

Abstract

Gouty arthritis is a characteristically intense acute inflammatory reaction that erupts in response to articular deposits of monosodium urate (MSU) crystals. Important recent molecular biologic advances in this field have given us a clear picture of the mechanistic basis of gouty inflammation. The innate immune inflammatory response is critically involved in the pathology of gout. Specifically, MSU crystals promote inflammation directly by stimulating cells via Toll-like receptor signaling and by providing a surface for cleavage of C5 and formation of complement membrane attack complex (C5b-9), culminating in secretion of cytokines, chemokines, and other inflammatory mediators with a dramatic influx of neutrophils into the joint. Despite the detailed mechanistic picture for gouty inflammation, there are no placebo-controlled, randomized clinical studies for any of the therapies commonly used, although comparative studies have demonstrated that many nonsteroidal anti-inflammatory drugs are equivalent to indomethacin with respect to controlling acute gouty attacks. In general, the first line of anti-inflammatory therapy for acute gout is nonsteroidal anti-inflammatory drugs, and the selective cyclo-oxygenase-2 inhibitor celecoxib can be used where appropriate. The second line of treatment is glucocorticosteroids, given systemically (oral, intravenous, or intramuscular) or intra-articularly. Alternatively, synthetic adrenocorticotropic hormone is effective, partly via induction of adrenal glucocorticosteroids and partly via rapid peripheral suppression of leukocyte activation by melatonin receptor 3 signaling. The third line of treatment is oral colchicine, which is highly effective when given early in an acute gouty attack, but it is poorly tolerated because of predictable gastrointestinal side effects.

Introduction

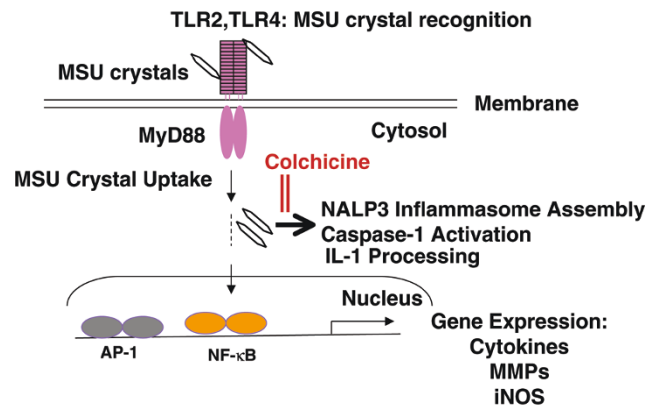
Gouty arthritis is a characteristically intense acute inflammatory reaction that erupts in response to articular deposits of monosodium urate (MSU) crystals. Tophi appear to continually recruit monocytes that differentiate to macrophages, and tophi also continually remodel [1], but it is now appreciated that uptake of MSU crystals by fully differentiated macrophages potentially exerts anti-inflammatory effects [2]. Important recent molecular biologic advances in this field have given us a clear picture of the mechanistic basis of how

gouty inflammation is triggered. An innate immune inflammatory response to the naked crystal surface, which probably sheds bound surface proteins, including anti-inflammatory crystal surface-bound apolipoprotein B [3] as the boundaries of MSU crystal deposits expand and contract, appears intimately involved in the pathology of gout [4,5]. The process involves terminal complement membrane attack complex formation triggered by C5 cleavage on the crystal surface [6] and the capacity of inert MSU crystals to turn on resident cells in the joint [7] and to induce generation of IL-8 and related CXC chemokine receptor-2 ligands [6,7].

As shown in Figure 1, recognition of the naked MSU crystal by Toll-like receptor (TLR)2 and TLR4, which are normally involved in triggering innate host defense responses to infectious pathogens, was recently discovered to be a primary trigger of the inflammatory and degenerative tissue reactions associated with gouty arthritis [4,5]. TLR2, TLR4, and the TLR adaptor protein MyD88 promote ingestion of the naked MSU crystal by phagocytes [5]. Furthermore, downstream of recognition by TLR2 and TLR4 of the MSU crystal, MyD88, Rac1, phosphatidylinositol-3 kinase, and Akt signaling transduce activation of the transcription factor nuclear factor- κ B and expression of a variety of pro-inflammatory molecules [4,5]. As also shown in Figure 1, intracellular assembly of the cytosolic NACHT-LRR-PYD-containing protein (NALP)3 (cryopyrin) inflammasome protein complex is subsequently triggered by ingested MSU crystals in phagocytes [8]. The inflammasome assembly in response to MSU crystals triggers caspase-1 activation and the maturation and release of IL-1 β in phagocytes, and the MSU crystal-induced NALP3 inflammasome protein complex assembly is suppressed by the microtubule inhibitor colchicine [8]. Other events linked to 'early induced innate immune response' in gouty inflammation include expression on infiltrating phagocytes of the 'triggering receptor expressed on myeloid cells' 1 (TREM-1) [9,10].

ACTH = adrenocorticotropic hormone; COX = cyclo-oxygenase; IL = interleukin; MSU = monosodium urate; NALP = NACHT-LRR-PYD-containing protein; NSAID = nonsteroidal anti-inflammatory drug; TLR = Toll-like receptor.

Figure 1



The innate immune response in recognition, uptake, and responses of cells to monosodium urate (MSU) crystals. As discussed in the text, recognition of the naked MSU crystal by the toll-like receptors 2 and 4 (TLR2, TLR4), which are normally involved in triggering innate host defense responses to infectious pathogens is a primary trigger of inflammatory and degenerative tissue reactions associated with gouty arthritis. TLR2, TLR4, and the TLR adaptor protein MyD88 promote ingestion of the naked MSU crystal by phagocytes. Downstream of TLR2 and TLR4 recognition of the MSU crystal, MyD88 transduces activation of the transcription factor NF- κ B and the expression of a variety of pro-inflammatory mediators. Intracellular assembly of the cytosolic NALP3 (cryopyrin) inflammasome protein complex is subsequently triggered by delivery to the inflammasome of ingested MSU crystals in phagocytes. The inflammasome assembly in response to MSU crystals triggers caspase-1 activation and the maturation and release of IL-1 β in phagocytes. MSU crystal-induced (but not ATP-induced) NALP3 inflammasome protein complex assembly is suppressed by high concentrations of the microtubule inhibitor colchicine, suggesting that a high concentration of colchicine blocks delivery of the crystals to the NALP3 inflammasome AP, activator protein; iNOS, inducible nitric oxide synthase; MMP, matrix metalloproteinase.

The primary pathologic hallmark of gout is neutrophil influx into the joint fluid [3], which is consistent with IL-1 and tumor necrosis factor- α -induced activation of endothelium with resulting expression of adhesion molecules for leukocytes [11,12]. Neutrophils accumulate in both the joint fluid and the synovial membrane, where a small fraction of these cells actively phagocytose MSU crystals and release mediators. These mediators include the abundant neutrophil cytosolic proteins S100A8/S100A9 (formerly termed 'crystal-induced chemotactic factor' [CCF]) [13,14], which are low-molecular-weight mediators, such as prostanoids and leukotrienes, that are chemotactic and amplify the inflammatory reaction. The model for the innate immune inflammatory response that drives the acute gouty attack was recently reviewed in detail [10].

Acute gouty attacks are by nature self limiting. Multiple mechanisms have been proposed for the spontaneous resolution of acute gout, including coating of crystals with protective proteins and changes in the balance of expression of proinflammatory and anti-inflammatory factors as the cell population within the inflamed joint changes [3]. The influx of

monocytes that follows on the heels of neutrophil influx in acute gout appears significant. As monocytes mature to macrophages, their response to MSU crystals changes from proinflammatory [15] to anti-inflammatory. Specifically, fully differentiated macrophages that ingest MSU crystals can release transforming growth factor- β_1 , a potent anti-inflammatory cytokine for MSU crystal-induced inflammation [16], which constitutes an anti-inflammatory crystal disposal mechanism [2,17,18]. Macrophage uptake of apoptotic neutrophils is also likely to be central to spontaneous resolution of gouty inflammation, again partly via release of transforming growth factor- β_1 [19].

Essentially, innate immune 'early induced' responses do not directly induce immunologic memory or durable protective immunity [10]. The stereotypic response in acute gout is consistent with the recurrent paroxysmal nature of the disease and the primary role in pathogenesis of 'professional phagocytes', unlike the case for inflammation driven by adaptive immune responses [10]. The breaching of tissue barriers by the MSU crystal can stimulate innate immune alternative complement pathway activation, expression of chemokines and certain other inflammatory cytokines, and uptake of the crystal by resident and recruited 'professional phagocytes' in a rapid effort to eliminate the noxious agent. It is remarkable that gout, the most ancient rheumatic disease, is driven by the most primitive form of the immune response [10].

Current pharmacologic options for acute gouty inflammation

Given the aforementioned mechanisms involved in triggering acute gout, anti-inflammatory agents are naturally the primary modality for treating acute attacks of gout, using the major options listed in Table 1. Nonsteroidal anti-inflammatory drugs (NSAIDs) such as indomethacin and naproxen are frequently used as first-line therapies for acute gout; however, these agents may have serious side effects such as gastrointestinal toxicity, renal toxicity, or gastrointestinal bleeding. Systemic corticosteroids have also exhibited significant efficacy in patients with acute gout; intra-articular corticosteroids are frequently used in patients with monarticular gout, particularly in patients who cannot receive oral therapy. Parenteral adrenocorticotropic hormone (ACTH) is also quite useful in treating acute gout, particularly in those patients with renal and/or gastrointestinal contraindications to other therapies. Synthetic ACTH is effective partly via induction of adrenal glucocorticosteroids, and partly via rapid peripheral suppression of leukocyte activation by melatonin receptor 3 signaling [20]. In patients with contraindications or who cannot tolerate NSAIDs or systemic (either oral or parenteral) corticosteroids, oral colchicine is generally the next choice for primary therapy. As the acute attack resolves it is appropriate to use low doses of oral colchicine as an adjunct to NSAID, glucocorticosteroid, or ACTH treatment, and continuation of low dose oral colchicine can help to suppress rebound flares after such treatment.

Table 1**Recommended treatment options for acute gouty arthritis**

Drug	Example regimens	Major considerations
NSAIDs (selected agents; no study has shown differences among NSAIDs in efficacy)		
Naproxen	750–1000 mg orally for 3 days followed by 500–750 mg orally daily for 4–7 days	There may be cost savings relative to other treatments for acute attacks Should be avoided in patients with renal or hepatic failure and patients at risk for clinically significant gastrointestinal events
Sulindac	300–400 mg orally for 7–10 days	Consider co-administration of PPI in patients at risk for clinically significant gastrointestinal events
Indomethacin	150–200 mg orally for 3 days followed by 100 mg orally daily for 4–7 days	
COX-2 inhibitors		
Celecoxib	400 mg orally on the first day, then 200 mg/day (in two divided doses) for 6–10 days	May provide better gastrointestinal tolerability than NSAIDs Gastrointestinal protective effect lost in patients taking concomitant aspirin Potential risk for cardiovascular adverse events, including hypertension
Systemic corticosteroids		
Prednisone	40–60 mg/day for 3 days, then decrease by 10–15 mg/day every 3 days until discontinuation	Avoid use if joint sepsis not excluded Avoid in patients subject to hyperglycemia
Methylprednisolone	100–150 mg per day for 1–2 days	
Triamcinolone acetonide	60 mg intramuscularly once	
Intra-articular corticosteroids		
Triamcinolone acetonide	10 mg in knees and 8 mg in small joints intra-articularly once	Only useful in patients with one or a few affected joints Avoid use if joint sepsis is not excluded
ACTH		
	25 USP units subcutaneously for acute small-joint monoarticular gout; 40 USP units intramuscularly or intravenously for larger joints or polyarticular gout	Not universally available Less effective in patients receiving long-term oral corticosteroid therapy Risk for corticotrophin hypersensitivity (less frequent with synthetic formulation)
Colchicine (oral)		
	For acute episodes within the first 24 hours in patients not already on prophylactic low-dose colchicine: 0.6 mg initially followed by additional doses of 0.6 mg every hour (typically for a total of three to four doses, but to a maximum of eight doses because more prolonged dosing often causes significant diarrhea, which can be accompanied by nausea and vomiting and may be severe enough to promote dehydration). This regimen can be used as an adjunct to other modalities and is typically followed by a daily low-dose oral colchicine regimen to prevent rebound	Avoid or reduce dose in elderly or frail patients or those with renal or hepatic dysfunction All patients who receive therapeutic dosages of colchicine will develop toxic effects Potential drug interactions with erythromycin, simvastatin, and cyclosporine; may increase risk for colchicine-induced toxic effects Avoid intravenous colchicines

Adapted with modifications from Terkeltaub RA [42]. ACTH, adrenocorticotrophic hormone; COX, cyclo-oxygenase; NSAID, nonsteroidal anti-inflammatory drug; PPI, proton pump inhibitor.

Only a single trial, conducted by Bellamy and colleagues [21], has examined the natural course of acute gout; in the absence of adequate placebo-controlled studies, this trial serves as a benchmark for comparing the efficacy of other treatments. In this 7-day study, two out of 11 patients

withdrew because of severe persistent pain after 4 days. All of the remaining patients showed some improvement in pain by day 5 and in swelling by day 7. Tenderness improved in seven of the nine remaining patients; however, full resolution of pain was observed in only three patients.

Few randomized controlled trials have been conducted to evaluate the efficacy of the various treatments for acute gouty arthritis. The data summarized below are – except where noted otherwise – from small, uncontrolled studies that were conducted in relatively heterogeneous patient populations. There remains a need for prospective evaluation of the efficacy and safety of treatments for acute gout.

Nonsteroidal anti-inflammatory drugs

Data suggest that generic NSAIDs can provide marked symptomatic relief within 24 hours of administration and may also provide substantial cost savings over other treatments for acute gout. NSAIDs have therefore become the drug of first choice in patients with acute attacks of gout who do not have underlying contraindications against their use.

Head-to-head studies of NSAIDs in patients with acute gouty arthritis suggest that there are few differences among these agents in terms of efficacy [22-24]. In an early study conducted by Smyth and Percy [25], indomethacin and phenylbutazone were compared in 28 patients (31 attacks). In this study, complete subjective relief from pain was obtained in a median of 5 days with both agents; the results for other outcome measures, including rest pain, tenderness, heat, erythema, swelling, and number of recurrences, were largely similar in the two treatment groups. In a second study, conducted by Altman and colleagues [26], 59 patients received double-blind treatment with ketoprofen 100 mg ($n = 29$) or indomethacin 50 mg ($n = 30$) three times a day. In both groups more than 90% of patients reported pain relief within the first day of treatment. After 5 days of treatment, seven ketoprofen patients and six indomethacin patients discontinued treatment because of complete or substantial pain relief. The majority of patients in both groups were rated as having marked improvement both by the investigators and by self-assessment.

The gastrointestinal adverse effects of traditional NSAIDs are well known. Clinically important NSAID-related events, such as gastrointestinal bleeding, result in more than 100,000 hospitalizations and 16,500 deaths each year in the USA alone. Endoscopic studies indicate that gastric or duodenal ulcers develop in between 15% and 30% of patients who regularly take these agents [27]. Other adverse effects of NSAIDs include reduced creatinine clearance, hyperkalemia, and elevations in liver enzymes. Elderly patients, those with established gastrointestinal disease, and those with impaired renal function are at greatest risk for NSAID-associated adverse effects [28]. The gastrointestinal side effects of NSAIDs may, in part, be lessened by co-administration of a proton pump inhibitor.

Together, these data indicate that the traditional NSAIDs are effective in the treatment of acute gout; however, the usefulness of NSAIDs is limited by their side effects, particularly given that patients with acute gout are likely to receive

relatively high dosages of these medications. Cyclooxygenase (COX)-2-specific inhibition may be useful in patients with acute gout, particularly those with established gastrointestinal disease or others who cannot tolerate the gastrointestinal adverse effects of traditional NSAIDs.

The efficacy of etoricoxib, a COX-2 inhibitor, was compared with that of indomethacin in 142 men and 8 women with acute gout [29]. Patients received etoricoxib 120 mg/day or indomethacin 50 mg three times a day for 8 days; therapy was initiated within 48 hours of symptom onset. The primary outcome measures of this study were patient assessment of pain in the affected joint over days 2–5 and investigator-assessed and patient-assessed pain and tenderness in the inflamed joint on a 0- to 4-point Likert scale. The efficacy of etoricoxib was similar to that of indomethacin for all efficacy end-points; however, drug-related adverse events were significantly less frequent among patients who received etoricoxib (22.7%) than among those who received indomethacin (46.7%).

These data suggest that COX-2 inhibitors – of which only celecoxib is available at the time of writing – are effective in treating acute gouty arthritis and may be associated with fewer adverse effects than traditional NSAIDs, at least in short-term treatment. Recently, concerns have been raised regarding the relationship between COX-2 inhibitors and cardiovascular adverse events; these concerns may limit the applicability of these agents in the prophylactic setting.

Corticosteroids

Systemic corticosteroids have been used for the treatment of acute gout since 1952. As with other treatments for gout, systematic studies of the efficacy of corticosteroids – both systemic therapy and intra-articular therapy – are lacking. However, at least at relatively large doses, systemic corticosteroid therapy appears to be associated with good responses and few important side effects.

In a study conducted by Groff and colleagues [30], patients with acute gout who had contraindications to NSAIDs received short-term therapy with systemic corticosteroids. Patients were treated with prednisone at dosages ranging from 20 to 50 mg/day, with a tapering schedule over a mean of 10.5 days ($n = 9$); three more difficult-to-manage patients received initial intravenous therapy with prednisolone or prolonged prednisone over 17 days. All patients except one noted improvement within 48 hours; complete resolution of the signs and symptoms of acute gout occurred within 7 days in 11 out of 13 episodes and within 10 days in the remainder. A systematic comparison of different systemic corticosteroid dosing regimens has not yet been conducted in patients with acute gout.

In a second study, reported by Alloway and colleagues [31], 27 patients with proven acute gout received indomethacin

50 mg three times daily or intramuscular triamcinolone acetonide 60 mg. Patients were followed for 30 days. The mean time to symptom resolution was 8 days among patients who received indomethacin and 7 days among those who received triamcinolone acetonide. Triamcinolone acetonide was not associated with rebound gout attacks or clinically important side effects.

A third study, conducted by Werlen and colleagues [32], evaluated the efficacy and safety of a single injection of intramuscular betamethasone (7 mg), intravenous methylprednisolone (125 mg), or diclofenac 50 mg three times daily for 3 days followed by 25 mg three times daily for an additional 3 days. Efficacy was evaluated by the treating physician after 1, 3, and 6 days based on the subjective global impression of outcomes and on a 4-point joint swelling scale. Among all patients enrolled in the study, more than 50% improvement was observed in 21 out of 25 patients after 24 hours of therapy. Among patients who received oral diclofenac, more than 50% improvement was observed in six out of nine patients; among patients who received intramuscular betamethasone or intravenous methylprednisolone, more than 50% improvement was observed in nine out of 10 and six out of six patients, respectively, 24 hours after therapy. Further improvements were observed in 23 out of 25 patients after 3 days. Overall, subjective improvement was more than 90% in 19 out of 25 patients after 6 days. No adverse effects were observed among patients who received diclofenac; among patients who received betamethasone one patient with established diarrhea developed hyperglycemia and one patient who received methylprednisolone developed hot flushes.

Intra-articular injections of corticosteroids are useful in cases involving one or few joints. The value of intra-articular corticosteroids is supported by the results of several small, open-label studies. Patients with polyarticular gout may benefit from intra-articular treatment of joints with persistent synovitis [33].

In a small case series reported by Fernandez and colleagues [34], 19 men (20 attacks) received triamcinolone acetonide (10 mg in knees and 8 mg in small joints). At this relatively low dosage, attacks were resolved in 11 joints (55%) at 24 hours and in nine joints (45%) at 48 hours. All attacks were fully resolved 48 hours after treatment.

Synthetic adrenocorticotrophic hormone

Parenteral ACTH is useful in acute gout, particularly in patients with renal and/or gastrointestinal contraindications to other therapies. The efficacy of ACTH in treating episodes of acute gout was retrospectively examined in a study conducted by Ritter and colleagues [35]. A total of 38 patients with acute gout and five patients with acute pseudogout with indications for ACTH therapy (including congestive heart failure, chronic renal insufficiency, gastrointestinal bleeding, or lack of response to an NSAID) received ACTH treatment. Patients received intravenous ($n = 27$), intra-

muscular ($n = 6$), or subcutaneous ($n = 5$) drug, most commonly at 40 IU every 8 hours followed by 40 IU every 12 hours and then 40 IU once daily; the duration of therapy ranged from 1 day to 12 days. Seventy-nine per cent of patients received prophylactic colchicine as the ACTH dose was tapered. All episodes of pseudogout resolved in a mean of 4.2 days; 97% of acute gout episodes resolved in an average of 5.5 days. There were three episodes of relapse despite the use of prophylactic colchicine and one relapse in a patient who did not receive colchicine. Mild hypokalemia, hyperglycemia, edema, and rebound arthritis occurred among patients receiving ACTH; however, all were controlled easily.

The efficacies of indomethacin and ACTH were compared in a prospective, quasi-randomized study conducted by Axelrod and Preston [36]. In this study, 100 male patients who presented with acute gouty arthritis (confirmed by crystal diagnosis) were alternately assigned to therapy with single intramuscular injection of ACTH (40 IU) or oral indomethacin (50 mg, four times daily) until pain abated. Each gout attack during a 1-year period was treated; during each treatment course patients were treated and observed for 5 hours before release. Seventy-six patients completed the study protocol; in these patients, the mean interval to relief from pain was significantly shorter among those assigned to ACTH (3 hours) than among those who received indomethacin (24 hours). Pain resolved within 4 hours. No adverse effects were observed among patients who received intramuscular ACTH. In contrast, a broad range of side effects – including gastrointestinal and neurologic adverse events – were observed among patients who received indomethacin.

A single prospective, randomized controlled trial of ACTH has been conducted. In this study, conducted by Siegel and colleagues [37], 31 patients with acute gout received either a single dose of intramuscular ACTH (40 IU; $n = 16$) or triamcinolone acetate (60 mg; $n = 15$). The time to complete resolution of symptoms was similar in the two groups (7.9 and 7.6 days, respectively). Patients who received triamcinolone acetate required fewer repeat injections compared with the ACTH group.

It is surprising that so few systematic studies on the best treatment of acute gouty arthritis have been carried out. Nonetheless, the literature does indicate that a number of efficacious therapies are available. The optimal therapy for any given patient should be tailored to that individual's needs. Fortunately, there are numerous options that all appear to be similarly efficacious. Nonetheless, prospective studies of the various therapies available for treating gout should be carried out to determine the best approaches to therapy.

Colchicine

Colchicine, an alkaloid derived from the autumn crocus *Colchicum autumnale*, has been used to treat inflammatory diseases for nearly 2000 years. However, it was not until

1920 that colchicine, the pharmacologically active derivative of the plant, was isolated. Colchicine has many pharmacologic effects that may contribute to its anti-inflammatory actions. The earliest effect to be demonstrated is the capacity of colchicine to block microtubule assembly in neutrophils and other inflammatory cells, an effect that leads to diminished phagocytosis and transport of MSU crystals to the lysosome [28]. Because of its ability to alter microtubule assembly, colchicine also alters the expression of a number of cell surface proteins, including downregulation of tumor necrosis factor- α receptors, insulin, and β -adrenergic agonists [38,39]. Colchicine also inhibits the release of chemotactic factors (including both peptide-derived and lipid-derived mediators such as leukotriene B₄ from neutrophils), specifically inhibits signaling for activation in neutrophils exposed to MSU crystals, and reduces adhesion and recruitment of polymorphonuclear leukocytes to the inflamed joint via suppression of neutrophil L-selectin expression and alteration of E-selectin distribution on stimulated endothelial cells. The recent, compelling demonstration of colchicine suppression of MSU crystal-induced NALP3 inflammasome-driven caspase-1 activation and IL-1 β processing [8] illustrates another substantial anti-inflammatory effect of colchicine. This effect likely occurs via microtubule inhibition, and impaired delivery of MSU crystals to the NALP3 inflammatory protein complex in the cytosol, and it requires relatively high (micromolar) concentrations of colchicine [8].

In treating acute gouty arthritis colchicine is typically administered as an oral 0.6 mg dose, followed by 0.6 mg at hourly intervals until gastrointestinal side effects (e.g. nausea, vomiting, or diarrhea) occur or a maximum total of six to eight doses has been administered. Many patients only require three to four doses of 0.6 mg oral colchicine to achieve substantial improvement. Limited dose oral colchicine regimens of this type, particularly if started within the first 24 hours of the gout flare, are useful because they can lessen the frequency of gastrointestinal toxicity, which sometimes is severe. In most patients, substantial relief is observed by 18 hours and diarrhea generally develops within 24 hours. Joint inflammation subsides over 48 hours in more than 75% of patients [28]. Colchicine is a potentially toxic drug that can result in fatal complications; indeed, colchicine probably has the smallest therapeutic window of any drug used to treat acute gouty arthritis. Intravenous colchicine has fewer gastrointestinal side effects than oral colchicine, although its primary and most worrisome complication is bone marrow suppression, which can be lethal.

The effects of oral colchicine in patients with acute gout have been studied in only one placebo-controlled trial. In this study, conducted by Ahern and colleagues [40], 43 patients were randomly assigned to placebo ($n = 21$) or to colchicine 1 mg followed by 0.5 mg every 2 hours until complete response or toxicity ($n = 22$); patients were not allowed to take NSAIDs during the study period. Approximately two-thirds of colchicine-treated patients improved after 48 hours,

compared with one-third of patients in the placebo group. Moreover, colchicine-treated patients responded to treatment earlier, with significant differences from placebo observed 18–30 hours from baseline. All 22 patients who received colchicine developed diarrhea after a median of 24 hours (range 12–36 hours) or after a mean dose of colchicine of 6.7 mg. In most patients, gastrointestinal side effects occurred before the relief of pain. Because the frequency of gastrointestinal toxicity with high-dose colchicine is essentially 100% and newer, less toxic agents are available for the treatment of acute gouty attacks, this regimen has fallen into disfavor and is not used often.

An alternative to the use of oral colchicine is intravenous colchicine. Although there is far less gastrointestinal toxicity with intravenous colchicine, its use has fallen into disfavor as a result of substantial systemic toxicities – particularly bone marrow suppression – and reports of 33 deaths between 1985 and 1997 [41]. These adverse effects may occur even with low doses of colchicine (<2 mg) in patients with hepatobiliary obstruction, renal insufficiency, and/or advanced age [42]. Extravasation of colchicine out of the vein can cause tissue necrosis. The use of intravenous colchicine should be avoided in the treatment of acute gout.

Conclusion

The molecular basis of acute gouty inflammation is well defined, but there is a lack of evidence from prospectively designed, randomized clinical trials on the best treatment for acute gout. Nonetheless, several approaches to the treatment of acute gouty arthritis appear to be efficacious. Well designed comparative clinical studies of these treatments are needed to refine evidence-based treatment decisions in acute gouty inflammation.

Competing interests

BNC has declared the following competing interests:

Intellectual property: Patents on use of adenosine A_{2A} receptor agonists to promote wound healing and use of A_{2A} receptor antagonists to inhibit fibrosis; a method for testing for genes associated with fibromyalgia; use patent for adenosine A₁ receptor antagonists for the treatment of osteoporosis and other conditions of the bone.

Consultant to: King Pharmaceutical (licensee of A_{2A} patents above); Bristol-Myers Squib; TAP Pharmaceuticals; Prometheus Laboratories; Regeneron (Westat, DSMB); Sepracor; Amgen; Merck.

Honoraria: Merck; TAP Pharmaceuticals; Amgen.

Stock: CanFite Biopharmaceuticals (value, if any, unknown).

References

- Schweyer S, Hemmerlein B, Radzun HJ, Fayyazi A: **Continuous recruitment, co-expression of tumour necrosis factor- α and matrix metalloproteinases, and apoptosis of macrophages in gout tophi.** *Virchows Arch* 2000, **437**:534-539.
- Yagnik DR, Hillyer P, Marshall D, Smythe CD, Krausz T, Haskard DO, Landis RC: **Noninflammatory phagocytosis of monosodium urate monohydrate crystals by mouse macrophages.**

- Implications for the control of joint inflammation in gout.** *Arthritis Rheum* 2000, **43**:1779-1789.
3. Terkeltaub R: **Pathogenesis and treatment of crystal-induced inflammation.** In *Arthritis and Allied Conditions*, 15th ed. Edited by Koopman WJ, Moreland LW. Philadelphia: Lippincott, Williams and Wilkins; 2004:2357-2372.
 4. Liu-Bryan R, Pritzker K, Firestein GS, Terkeltaub R: **TLR2 signaling in chondrocytes drives calcium pyrophosphate dihydrate and monosodium urate crystal-induced nitric oxide generation.** *J Immunol* 2005, **174**:5016-5023.
 5. Liu-Bryan R, Scott P, Sydlaske A, Rose DM, Terkeltaub R: **Innate immunity conferred by toll-like receptors 2 and 4 and myeloid differentiation factor 88 expression is pivotal to monosodium urate monohydrate crystal-induced inflammation.** *Arthritis Rheum* 2005, **52**:2936-2946.
 6. Tramontini N, Huber C, Liu-Bryan R, Terkeltaub RA, Kilgore KS: **Central role of complement membrane attack complex in monosodium urate crystal-induced neutrophilic rabbit knee synovitis.** *Arthritis Rheum* 2004, **50**:2633-2639.
 7. Terkeltaub R, Baird S, Sears P, Santiago R, Boisvert W: **The murine homolog of the interleukin-8 receptor CXCR-2 is essential for the occurrence of neutrophilic inflammation in the air pouch model of acute urate crystal-induced gouty synovitis.** *Arthritis Rheum* 1998, **41**:900-909.
 8. Martinon F, Petrilli V, Mayor A, Tardivel A, Tschopp J: **Gout-associated uric acid crystals activate the NALP3 inflammasome.** *Nature* 2006 [Epub ahead of print].
 9. Murakami Y, Akahoshi T, Hayashi I, Endo H, Kawai S, Inoue M, Kondo H, Kitasato H: **Induction of triggering receptor expressed on myeloid cells 1 in murine resident peritoneal macrophages by monosodium urate monohydrate crystals.** *Arthritis Rheum* 2006, **54**:455-462.
 10. Liu-Bryan R, Terkeltaub R: **Evil humors take their toll as innate immunity makes gouty joints TREM-ble.** *Arthritis Rheum* 2006, **54**:383-386.
 11. Chapman PT, Yarwood H, Harrison AA, Stocker CJ, Jamar F, Gundel RH, Peters AM, Haskard DO: **Endothelial activation in monosodium urate monohydrate crystal-induced inflammation: in vitro and in vivo studies on the roles of tumor necrosis factor alpha and interleukin-1.** *Arthritis Rheum* 1997, **40**:955-965.
 12. Landis RC, Haskard DO: **Pathogenesis of crystal-induced inflammation.** *Curr Rheumatol Rep* 2001, **3**:36-41.
 13. Ryckman C, McColl SR, Vandal K, de Medicis R, Lussier A, Poubelle PE, Tessier PA: **Role of S100A8 and S100A9 in neutrophil recruitment in response to monosodium urate monohydrate crystals in the air-pouch model of acute gouty arthritis.** *Arthritis Rheum* 2003, **48**:2310-2320.
 14. Ryckman C, Gilbert C, de Medicis R, Lussier A, Vandal K, Tessier PA: **Monosodium urate monohydrate crystals induce the release of the proinflammatory protein S100A8/A9 from neutrophils.** *J Leukoc Biol* 2004, **76**:433-440.
 15. Terkeltaub R, Zachariae C, Santoro D, Martin J, Peveri P, Matsushima K: **Monocyte-derived neutrophil chemotactic factor/interleukin-8 is a potential mediator of crystal-induced inflammation.** *Arthritis Rheum* 1991, **34**:894-903.
 16. Liote F, Prud'hommeaux F, Schiltz C, Champy R, Herbelin A, Ortiz-Bravo E, Bardin T: **Inhibition and prevention of monosodium urate monohydrate crystal-induced acute inflammation in vivo by transforming growth factor beta1.** *Arthritis Rheum* 1996, **39**:1192-1198.
 17. Yagnik DR, Evans BJ, Florey O, Mason JC, Landis RC, Haskard DO: **Macrophage release of transforming growth factor beta1 during resolution of monosodium urate monohydrate crystal-induced inflammation.** *Arthritis Rheum* 2004, **50**:2273-2280.
 18. Landis RC, Yagnik DR, Florey O, Philippidis P, Emons V, Mason JC, Haskard DO: **Safe disposal of inflammatory monosodium urate monohydrate crystals by differentiated macrophages.** *Arthritis Rheum* 2002, **46**:3026-3033.
 19. Fadok VA, Bratton DL, Konowal A, Freed PW, Westcott JY, Henson PM: **Macrophages that have ingested apoptotic cells in vitro inhibit proinflammatory cytokine production through autocrine/paracrine mechanisms involving TGF-beta, PGE2, and PAF.** *J Clin Invest* 1998, **101**:890-898.
 20. Getting SJ, Christian HC, Flower RJ, Perretti M: **Activation of melanocortin type 3 receptor as a molecular mechanism for adrenocorticotropic hormone efficacy in gouty arthritis.** *Arthritis Rheum* 2002, **46**:2765-2775.
 21. Bellamy N, Downie WW, Buchanan WW: **Observations on spontaneous improvement in patients with podagra: implications for therapeutic trials of nonsteroidal anti-inflammatory drugs.** *Br J Clin Pharmacol* 1987, **24**:33-36.
 22. Weiner GI, White SR, Weitzner RI, Rubinstein HM: **Double-blind study of fenoprofen versus phenylbutazone in acute gouty arthritis.** *Arthritis Rheum* 1979, **22**:425-426.
 23. Shrestha M, Morgan DL, Moreden JM, Singh R, Nelson M, Hayes JE: **Randomized double-blind comparison of the analgesic efficacy of intramuscular ketorolac and oral indomethacin in the treatment of acute gouty arthritis.** *Ann Emerg Med* 1995, **26**:682-686.
 24. Maccagno A, Di Giorgio E, Romanowicz A: **Effectiveness of etodolac ('Lodine') compared with naproxen in patients with acute gout.** *Curr Med Res Opin* 1991, **12**:423-429.
 25. Smyth CJ, Percy JS: **Comparison of indomethacin and phenylbutazone in acute gout.** *Ann Rheum Dis* 1973, **32**:351-353.
 26. Altman RD, Honig S, Levin JM, Lightfoot RW: **Ketoprofen versus indomethacin in patients with acute gouty arthritis: a multi-center, double blind comparative study.** *J Rheumatol* 1988, **15**:1422-1426.
 27. Laine L: **Nonsteroidal anti-inflammatory drug gastropathy.** *Gastrointest Endosc Clin N Am* 1996, **6**:489-504.
 28. Emmerson BT: **The management of gout.** *N Engl J Med* 1996, **334**:445-451.
 29. Schumacher HR Jr, Boice JA, Daikh DI, Mukhopadhyay S, Malmstrom K, Ng J, Tate GA, Molina J: **Randomised double blind trial of etoricoxib and indometacin in treatment of acute gouty arthritis.** *BMJ* 2002, **324**:1488-1492.
 30. Groff GD, Franck WA, Raddatz DA: **Systemic steroid therapy for acute gout: a clinical trial and review of the literature.** *Semin Arthritis Rheum* 1990, **19**:329-336.
 31. Alloway JA, Moriarty MJ, Hoogland YT, Nashel DJ: **Comparison of triamcinolone acetonide with indomethacin in the treatment of acute gouty arthritis.** *J Rheumatol* 1993, **20**:111-113.
 32. Werlen D, Gabay C, Vischer TL: **Corticosteroid therapy for the treatment of acute attacks of crystal-induced arthritis: an effective alternative to nonsteroidal antiinflammatory drugs.** *Rev Rhum Engl Ed* 1996, **63**:248-254.
 33. Gray RG, Tenenbaum J, Gottlieb NL: **Local corticosteroid injection treatment in rheumatic disorders.** *Semin Arthritis Rheum* 1981, **10**:231-254.
 34. Fernandez C, Noguera R, Gonzalez JA, Pascual E: **Treatment of acute attacks of gout with a small dose of intraarticular triamcinolone acetonide.** *J Rheumatol* 1999, **26**:2285-2286.
 35. Ritter J, Kerr LD, Valeriano-Marcet J, Spiera H: **ACTH revisited: effective treatment for acute crystal induced synovitis in patients with multiple medical problems.** *J Rheumatol* 1994, **21**:696-699.
 36. Axelrod D, Preston S: **Comparison of parenteral adrenocorticotropic hormone with oral indomethacin in the treatment of acute gout.** *Arthritis Rheum* 1988, **31**:803-805.
 37. Siegel LB, Alloway JA, Nashel DJ: **Comparison of adrenocorticotropic hormone and triamcinolone acetonide in the treatment of acute gouty arthritis.** *J Rheumatol* 1994, **21**:1325-1327.
 38. Cronstein BN, Molad Y, Reibman J, Balakhane E, Levin RI, Weissman G: **Colchicine alters the quantitative and qualitative display of selectins on endothelial cells and neutrophils.** *J Clin Invest* 1995, **96**:994-1002.
 39. Spilberg I, Mandell B, Mehta J, Simchowicz L, Rosenberg D: **Mechanism of action of colchicine in acute urate crystal-induced arthritis.** *J Clin Invest* 1979, **64**:775-780.
 40. Ahern MJ, Reid C, Gordon TP, McCredie M, Brooks PM, Jones M: **Does colchicine work? the results of the first controlled study in acute gout.** *Aust N Z J Med* 1987, **17**:301-304.
 41. Bonnel RA, Villalba ML, Karwoski CB, Beitz J: **Deaths associated with inappropriate intravenous colchicine administration.** *J Emerg Med* 2002, **22**:385-387.
 42. Terkeltaub RA: **Clinical practice. Gout.** *N Engl J Med* 2003, **349**:1647-1655.