

REVIEW

An emerging player in knee osteoarthritis: the infrapatellar fat pad

Andreea Ioan-Facsinay* and Margreet Kloppenburg

Abstract

The role of inflammation in the development, progression, and clinical features of osteoarthritis has become an area of intense research in recent years. This led to the recognition of synovitis as an important source of inflammation in the joint and indicated that synovitis is intimately associated with pain and osteoarthritis progression. In this review, we discuss another emerging source of inflammation that could play a role in disease development/progression: the infrapatellar fat pad (IFP). The aim of this review is to offer a comprehensive view of the pathology of IFP as obtained from magnetic resonance studies, along with its characterization at both the cellular and the molecular level. Furthermore, we discuss the possible function of this organ in the pathological processes in the knee by summarizing the knowledge regarding the interactions between IFP and other joint tissues and discussing the pro- versus anti-inflammatory functions this tissue could have. We hope that this review will offer an overview of all published data regarding the IFP and will indicate novel directions for future research.

Introduction

Hoffa's fat pad (infrapatellar fat pad, or IFP) is an intracapsular and extrasynovial adipose tissue structure in the knee joint. IFP has long been believed to be mostly structural adipose tissue, with little or no metabolic responses. Owing to mainly anatomical considerations, IFP is thought to contribute to the enlargement of the synovial area and this could improve the distribution of lubricant in the knee joint [1]. Although its importance for knee physiology is difficult to establish, early studies have indicated that IFP is preserved even under extreme starvation conditions in which the subcutaneous (sc)

adipose tissue is eliminated, and this suggested the critical importance of this fat depot for the knee function [2]. Besides these theoretical considerations, however, it is still unclear how IFP could contribute to knee function.

Nevertheless, recent accumulating evidence suggests that, besides synovium, cartilage, and bone, the IFP could be an important player in osteoarthritis (OA) [3]. In this review, we propose to summarize published data regarding the inflammatory/immunological characteristics of this adipose tissue and to discuss the possible protective versus damaging role this adipose tissue could play in the inflammatory reactions in OA.

Pathology of infrapatellar fat pad

In 1904, Hoffa described inflammatory hyperplasia and hypertrophy of a knee adipose tissue, which later became known as Hoffa's fat pad or IFP. In this first report, IFP was also characterized by fibrosis and calcifications that were believed to be caused by trauma [4]. Knee pain with impaired knee mobility and swelling of the knee joint on both sites of the patella could be observed, even in the absence of arthritis. These features were collectively called Hoffa's disease, also known as IFP impingement, and were generally a result of repeated microtrauma. Other pathologies described in the IFP are ganglions, osteochondromas, localized nodular synovitis, and postoperative changes. Pathologies in the IFP can coincide with injuries of the anterior cruciate ligament and meniscal abnormalities [1,5].

Anterior knee pain is thought to be associated with pathology of the IFP. Since the IFP is extensively innervated, the IFP is exquisitely sensitive as are the anterior synovial tissue and capsule [6]. The presence of sensory nerve fibers in the IFP and its sensitivity were confirmed by nociceptive stimulation of the IFP by injection of hypertonic saline, which led to anterior knee pain [7].

* Correspondence: a.ioan@lumc.nl
Department of Rheumatology, Leiden University Medical Center,
Albinusdreef 2, 2333ZA, Leiden, The Netherlands

Infrapatellar fat pad on magnetic resonance imaging

IFP can be well visualized on magnetic resonance imaging (MRI), especially in the sagittal planes. Within the IFP, signal alterations in IFP can be observed on non-contrast-enhanced MRI. How these signal alterations on MRI compare with histology is not clear. These signal changes have been interpreted and used as surrogates for peripatellar synovitis in several clinical and epidemiological studies and in the Boston-Leeds Osteoarthritis Knee score scoring system [8-16]. Some of these MRI studies have shown an association between signal alterations in IFP and knee pain [9,10] or cartilage loss [17], which confirms IFP as a possible source of pain in the joint. Whether these signals are indeed associated with inflammation in IFP or rather synovial tissue inflammation is difficult to establish and remains to be determined. Also, edema in the IFP is visualized on MRI and is shown to be associated in cross-sectional studies with impingement and femoropatellar maltracking [18,19].

The presence of knee synovitis detected by MRI has been shown to correlate with synovial infiltrates and synovial hyperplasia in histological samples in both early and end-stage OA [20,21]. The best results have been obtained when contrast-enhanced MRI images were used [22]. Studies comparing both contrast-enhanced and non-contrast-enhanced MRI images revealed that signal alterations on non-contrast-enhanced MRI in IFP are sensitive but not specific for peripatellar synovitis as visualized on contrast-enhanced MRI and that these signal alterations also reflect non-specific alterations possibly unrelated to synovitis [17,23]. Studies separately assessing and investigating signal alterations in IFP and joint effusion on non-contrast-enhanced MRI images gave controversial results: some indicated that effusion was associated with pain or cartilage loss, while signal alterations in IFP were not [13,15,24], while others indicated the opposite [14]. Crema and colleagues [23] showed, in a study comparing signal alterations in IFP on non-contrast-enhanced MRI images with peripatellar synovial thickness on contrast-enhanced MRI images, that pain is associated with peripatellar synovial thickness and not with signal alterations in IFP itself.

In conclusion, the IFP is well innervated and can be a source of pain. The IFP is well visualized on MRI images and, within the IFP, signal alterations can be observed by non-contrast-enhanced MRI. These signal alterations are associated with peripatellar synovitis but also seem to reflect non-specific alterations. Whether signal alterations in IFP are clinically meaningful (that is, painful or associated with cartilage damage) or are just a biomarker for effusion or peripatellar synovitis is unclear and needs further investigation.

Infrapatellar fat pad is comparable to other adipose tissues in structure and function

MRI studies have shown that IFP is similar to sc adipose tissue in appearance, as it contains fibrous structures dispersed through adipocytes [25]. Histologically, IFP appears also fibrous and difficult to cut, but its appearance is different to that of sc adipose tissue of the thigh and resembles more the visceral adipose tissue (A Ioan-Facsinay and M Kloppenburg, unpublished data). Adipose tissue is highly flexible in volume, as adipocytes grow or shrink following storage or release of energy depending on the metabolic needs of the individual. Additionally, changes in adipose tissue volume result from differentiation of pre-adipocytes into mature adipocytes within adipose tissue. Most information about the volume of IFP has been obtained by using imaging techniques such as MRI. The first studies showing that the volume of IFP can vary considerably between individuals date back to 1974 [2], but a more recent study has confirmed these data by using 3-Tesla contrast MRI in 15 controls and 15 patients with OA [26]. The average volume of the IFP was, however, similar in the two study groups, despite large differences in body mass index (BMI), and was not associated with BMI in either group, indicating that, unlike in sc and visceral adipose tissues, systemic metabolic changes do not affect the IFP significantly. This is surprising in view of our own unpublished data indicating that the volume of both sc and IFP adipocytes is correlated to the BMI of the donor (data not shown) and in view of recently published data indicating that IFP is metabolically active and displays both basal and hormone-induced lipolysis [27], suggesting that it can be influenced by systemic factors. Together, these data indicate that IFP is a bona fide adipose tissue that can be responsive to systemic metabolic stimuli.

Infrapatellar fat pad of patients with osteoarthritis is a source of cytokines/adipokines

The inflammatory character of IFP has been investigated mostly during the last decade, when it became clear that adipose tissue not only is a site of storage and release of energy but also can be inflammatory and can affect other inflammatory/immune reactions either systemically or locally [28,29]. The first report about the inflammatory character of IFP dates back to 2003, when Ushiyama and colleagues [30] showed that IFP homogenates from patients with OA contain detectable levels of IL-6 and TNF α but also vascular endothelial growth factor and fibroblast growth factor bFGF. As these cytokines were also detected in synovial fluid of the same patients, these data are the first to indicate that IFP could be a source of cytokines/chemokines in the knee joint. Later studies showed more directly that IFP actively secretes IL-6 and its soluble receptor, sIL-6R, at higher levels than sc adipose tissue from the same patients [31] and showed

secretion of TNF α and various adipokines from this tissue [32]. Adipokines have long been believed to be cytokines secreted specifically by adipose tissue (hence their name). Therefore, they became the subject of intense investigation during the last years, as the role of adipose tissue-derived factors in obesity-related diseases became clearer. Similar to other adipose tissue depots, IFP is a source of adipokines such as adiponectin, adiponisin, leptin, resistin, and visfatin. With the exception of leptin and resistin, the other adipokines were more actively secreted by IFP than by sc adipose tissue of the same patients [31,32]. Surprisingly, however, two other studies indicated that IFP is not the only joint tissue secreting adipokines [33,34]. Therefore, the relative contribution of IFP to the adipokine levels found in synovial fluid remains to be determined. Adipokine release by IFP from healthy individuals is challenging to investigate because of difficulties in obtaining tissues from non-diseased individuals. Only in one study was control IFP tissue used from patients with early-stage OA and this study indicates that both adiponectin and leptin transcripts are upregulated at later stages of the disease [35], implying a possible association of these adipokines with disease severity.

Infrapatellar fat pad of patients with osteoarthritis is a source of lipid mediators

Besides secreting adipokines and cytokines, adipose tissue secretes lipids as a result of its main biological function: storage and release of energy. The main lipids secreted in this process are fatty acids released in the process of lipolysis. Interestingly, fatty acids not only are an important source of energy for tissues but also display immune modulatory properties. The pro-inflammatory effects of saturated fatty acids such as palmitic acid and the mostly anti-inflammatory effects of unsaturated fatty acids have been extensively explored in some diseases and are nowadays largely known [36,37]. Epidemiological studies have indicated that consumption of saturated fatty acids is associated with a higher incidence of cardiovascular diseases and diabetes type 2 but that consumption of (poly)unsaturated fatty acids is associated with protection from these diseases. The molecular mechanisms underlying these observations are still under scrutiny but could include changes in membrane fluidity, initiation of intracellular signaling events through specific receptors, or modulation of signaling induced by other molecules involved in metabolism, binding to transcription factors such as peroxisome proliferator-activated receptor (PPAR) and others (reviewed in [38,39]). Additionally, fatty acid derivatives, such as oxylipids, have very potent immune modulatory properties, being biologically relevant at picomolar and nanomolar concentrations. These oxylipids can have either pro- or anti-inflammatory/resolving properties, depending on their fatty acid precursor and the oxidizing

enzymes involved in their synthesis. Some of these are well known, such as prostaglandins (PGs), leukotrienes, and lipoxins derived from arachidonic acid, while others have been emerging during the past decade and have been recently characterized, such as resolvins, maresins, and protectins, derived from docosahexaenoic acid and eicosapentaenoic acid [40].

In a preliminary study, we have investigated whether IFP can release free fatty acids and their hydroxylated derivatives in a limited number of tissues derived from patients with end-stage OA. In adipocyte-conditioned medium obtained by culturing IFP-derived adipocytes overnight, we could show the presence of free fatty acids such as oleic, linoleic, palmitic, and palmitoleic acids. Interestingly, we could also detect significant levels of monohydroxylated derivatives of arachidonic acid and 5-, 12-, and 15-HETE as well as PGE2 and the novel pro-resolving lipid mediator PD1 [41]. These were also detectable in fat-conditioned media (FCM) obtained by culturing IFP explants overnight (unpublished data). These data indicate that OA IFP is a source of various soluble mediators with pro- as well as anti-inflammatory properties. Interestingly, similar results were found in a recent study, in which lipidomics analyses of FCM of IFP from OA patients undergoing joint-replacement surgery were compared with IFP-conditioned media of healthy individuals (post-mortem tissues). The results of this study indicated that various lipid species are different between OA and healthy tissues, the most remarkable difference being that FCM from healthy individuals contained elevated levels of the anti-inflammatory lipid mediator lipoxin A4 and reduced levels of thromboxane B2 and arachidonic acid compared with OA FCM [42]. Although these data await replication, they are indicative of a more pro-inflammatory lipid profile signature of OA IFP than of IFP from healthy individuals. However, because both pro- and anti-inflammatory mediators have been described to be released by IFP, the combined effect of these mediators is difficult to predict. Remarkably, we have found an association between the TNF α secreted by IFP and the BMI of the IFP donor, which suggests BMI-related changes in this adipose tissue and an enhanced state of inflammation with obesity [32]. However, the number of samples was limited, meaning that future studies are needed to further address the question of whether IFP-secreted soluble mediators change with increasing adiposity. Of great interest would be to further study whether these changes could explain the obesity-associated changes in disease parameters, such as radiographic damage and pain.

Infrapatellar fat pad as a site of inflammatory cells

Adipose tissue, including IFP, is composed mainly of adipocytes, the tissue-specific cells. However, as has become clear during the last decade, adipose tissue is also a site

where immune cells are present. The type and relative abundance of various immune cells, such as macrophages, mast cells, natural killer (NK) cells, NKT cells, T cells, and B cells, are variable and depend on both the type of adipose tissue investigated and the adiposity of the individual [43]. As shown primarily in murine studies, there is an increasing number of infiltrating immune cells with a pro-inflammatory phenotype in the obese adipose tissue (reviewed in [44]). For human adipose tissue, these data are less clear, although increasing numbers of macrophages and T cells have been shown in sc and omental adipose tissue of obese individuals [45-47]. The infiltrating immune cells are believed to interact with the tissue-resident adipocytes and this leads to reciprocal modulation and finally to changes in the inflammatory character of the adipose tissue. Therefore, characterizing the immune cells in adipose tissue is an important component of elucidating its inflammatory character.

Similar to other adipose tissues, the IFP contains a significant number of stromal vascular cells composed of CD45⁺ hematopoietic cells (approximately 30%), CD31⁺ endothelial cells (approximately 15%), and other cells (A Ioan-Facsinay and M Kloppenburg, unpublished data). Among the CD45⁺ cells, the most predominant were macrophages, followed by T cells, mast cells, and B cells [32]. Phenotypic characterization of these cells indicated that both CD4⁺ and CD8⁺ T cells display a predominant memory phenotype and contain a significant percentage of activated cells bearing the activation markers CD25 or CD69. This indicates that these cells could be locally activated by antigen and could secrete cytokines. Further investigation of the cytokines they could secrete revealed that T cells in IFP have a predominant T helper (Th)1 phenotype, secreting mainly IFN γ and TNF α upon *in vitro* stimulation and very little, if any, IL-10, IL-4, IL-17, and IL-22. For macrophages, phenotypic characterization indicated a mixed pro- and anti-inflammatory phenotype, as most cells expressed the M2 marker CD206 but secreted mostly IL-6 and TNF α and less IL-10 upon *in vitro* stimulation ([32] and our unpublished data). Part of these data were confirmed in another study in which CD206 expression on IFP macrophages has been confirmed by immunohistochemistry [48].

These data are in line with the analyses of soluble mediators from IFP, supporting the hypothesis that IFP displays a mixed pro- and anti-inflammatory phenotype. Interestingly, no association with BMI has been reported for any of the cell types described in IFP. Whether this is due to a lack of sufficient statistical power in the published studies or reflects a true finding remains to be established.

Infrapatellar fat pad as a source of mesenchymal stem cells

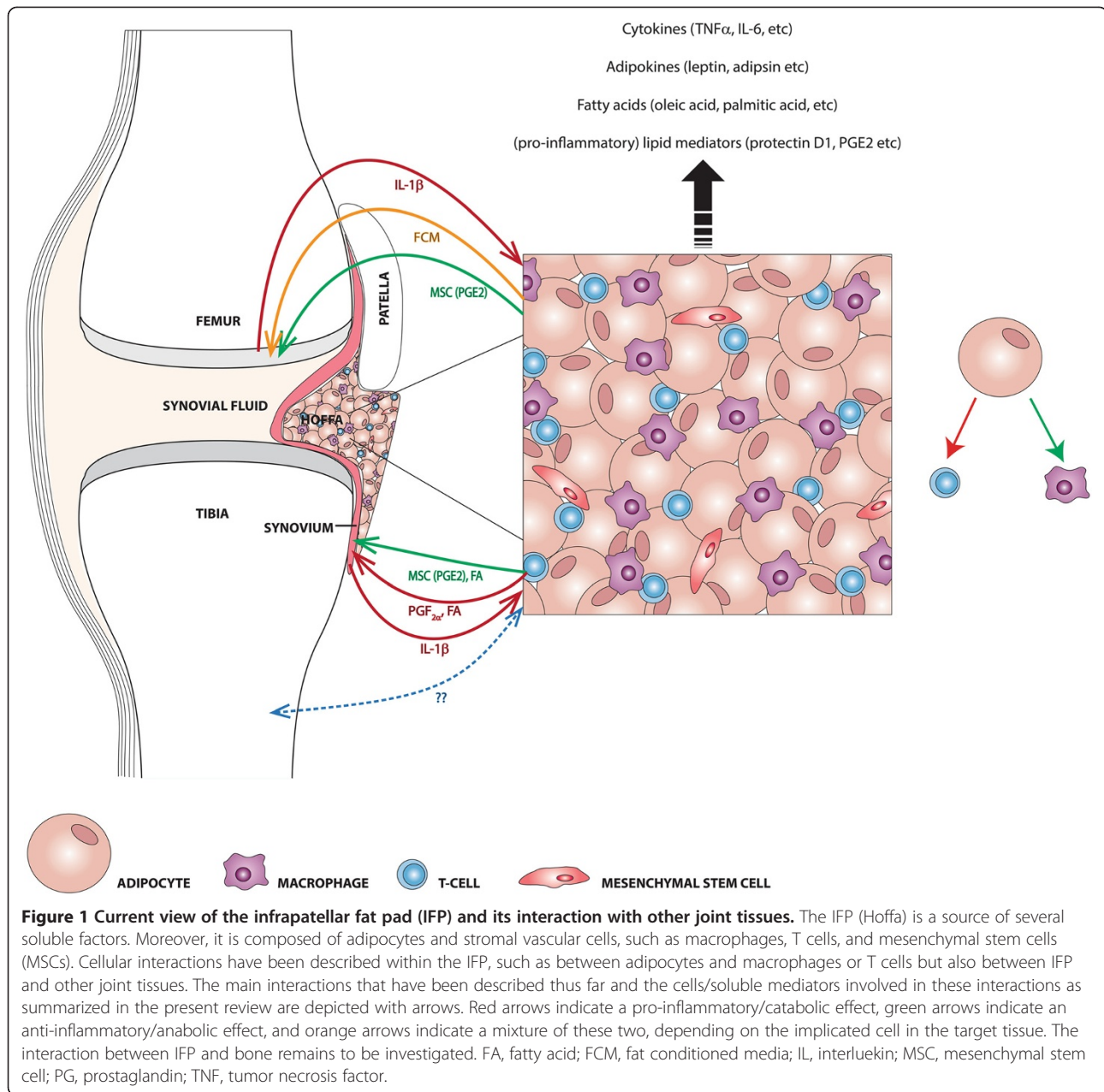
Research concerning the use of bone marrow-derived mesenchymal stem cells (MSCs) for tissue engineering has

grown explosively during the last 20 years [49]. Several publications have shown that these stem cells are multipotent and can differentiate into chondrocytes, bone, adipocytes, and fibroblasts and can modulate native and adaptive immunity. More recently, the discovery that stem cells exist in almost all tissues of our body [50] has led to intensive investigation of tissue-resident stem cells and their potency to be used in tissue regeneration. Because the adipose tissue is easily accessible and available in relatively large amounts, adipose tissue-derived stem cells could be attractive tools for therapy, especially since they share several biological characteristics with bone marrow-derived MSCs (reviewed in [51]). First reports showing that MSCs are present also in the IFP were published in the beginning of the 20th century. These publications show that IFP-derived stromal vascular cells that share common surface markers with bone marrow-derived stem cells are capable of differentiating toward cartilage, bone, or adipocytes *in vitro* [52], but also when transferred into severe combined immunodeficiency mice *in vivo* [53]. Owing to limitations in obtaining IFP from healthy individuals, most of these studies have been performed with IFP obtained from total knee replacement surgeries of patients with OA. Therefore, insights into the multipotency and efficiency of differentiation into different lineages of MSCs from IFP of OA versus healthy individuals are lacking. Comparison between MSCs from IFP, sc adipose tissue, bone marrow, and synovial fluid of patients with OA has indicated that IFP MSCs are most similar in phenotype (that is, surface marker expression) to sc adipose tissue MSCs but have proliferative and chondrogenic differentiation capacities most similar to bone marrow MSCs [54]. However, in a different study, IFP MSCs displayed enhanced chondrogenic and adipogenic capacity when compared with normal bone marrow MSCs [55], although differences in age between the OA and healthy population could account for this difference. Remarkably, no differences were observed in the osteogenic differentiation capacity of IFP MSCs in published studies.

Whether IFP MSCs would have similar differentiation/proliferative capacities also in the microenvironment of the OA joint remains to be investigated. However, it is interesting to mention that IFP-derived MSCs display an enhanced chondrogenic activity when differentiated *in vitro* under hypoxic conditions usually associated with inflammation [56]. Although the stromal vascular cells proliferated less under hypoxic conditions, they were characterized by increased synthesis of matrix components such as aggrecan and collagen, indicating that the regenerative properties of these cells are stimulated under cellular stress [56].

Interaction of infrapatellar fat pad with other joint tissues

To gain insight into the role of IFP in the joint, it is important to investigate its interaction with the other tissues



known to be involved in the pathophysiology of OA: synovium, cartilage, and bone. Although the interaction between IFP and bone or bone progenitors has not yet been investigated, some publications indicate a crosstalk between IFP and synovium, synovial cells, or cartilage.

The interaction with cartilage has been studied *in vitro* in co-cultures of FCM derived from IFP and cartilage explants. Contradictory results have been reported in two different studies. One of these reported that IFP-derived FCM of patients with OA induced enhanced expression of matrix metalloproteinase (MMP)1 and MMP13 and enhanced collagen release from bovine cartilage either in itself or in combination with IL-1 α [57].

In contrast, another study showed a protective role for IFP-derived FCM of patients with OA on cartilage by inhibiting nitric oxide (NO) production, glycosaminoglycan release, and MMP1 expression and reducing the effects of IL-1 β on NO production and MMP1 and MMP3 expression and enhancing collagen II production by bovine chondrocytes [48]. The reason for this discrepancy is unknown, but differences in experimental set-up, especially time length of the experiments, could account for differences in outcome.

To the best of our knowledge, the influence of IFP on synovium has not yet been investigated. However, in a recent study, the effects of FCM on synoviocyte function

have been investigated. The authors have shown that FCM had a pro-fibrotic effect on synoviocytes, which could be partially inhibited by blocking PGF2 α [58].

Reciprocally, synovium and cartilage could also modulate the IFP. Although this has not been shown yet *in vivo* or in co-culture experiments, there is one publication showing that IL-1 β , known to be secreted by OA cartilage and inflamed synovium, could influence IFP. This recent study has shown that IFP explants of patients with OA stimulated with IL-1 β secrete higher levels of mainly pro-inflammatory cytokines such as PTGS2, IL-1 β , MCP-1, and IL-6 and this effect can be partially inhibited by PPAR α activation [59]. These data support the hypothesis that there could be a crosstalk between cartilage/synovium and IFP that could play a role in the inflammatory processes in OA.

Additional data are available on the influence of IFP-derived cells, such as adipocytes and MSCs, on synovial cells or chondrocytes. Confirming the long-known immunomodulatory effects of MSCs, a recent study has shown that MSCs derived from various adipose tissues, including IFP (of patients with OA), can inhibit secretion of pro-inflammatory cytokines/chemokines from OA synovium and chondrocytes [60]. Both tissues were modulated in a similar manner, and for both synovium and chondrocytes the modulation was not dependent on the source of MSCs, but rather on their own inflammatory character: inflammatory synovia and chondrocytes were modulated more than their less inflammatory counterparts. Interestingly, these inhibitory effects could be mimicked by addition of PGE2 to synovium/chondrocytes and MSCs were shown to secrete PGE2, suggesting a possible involvement of this lipid mediator in the suppressive effects of MSCs.

The IFP is composed mainly of adipocytes. These also contribute largely to the secretory profile of IFP, as they are a rich source of adipokines and cytokines such as IL-6 [32]. Based on previous data indicating that there is a cross-talk between adipocytes and immune cells and that this can be mediated by soluble factors released by adipocytes [61], it is conceivable that this mechanism could be involved also in modulation of synovial cells by IFP. Among the most abundant immune cells present in the OA synovium are macrophages and CD4⁺ T cells [62]. We have found that these cells can be modulated by adipocytes derived from IFP and that lipids—in particular, free fatty acids—are potent mediators of this modulation [27,41]. Interestingly, the modulation of these two cell types seems to have different outcomes. Indeed, IFP-derived adipocyte-conditioned medium (ACM) induces a strongly enhanced proliferation and cytokine production by activated CD4⁺ T cells, indicating a pro-inflammatory effect on this cell population. This effect could be especially important considering

that the CD4⁺ T cells in OA synovium have predominantly a Th1 phenotype (unpublished data), which could be enhanced by IFP. On macrophages, however, the effect of IFP-derived ACM is less easy to interpret. Activation of monocyte-derived macrophages in the presence of ACM leads to inhibition of IL-12p40 secretion and this effect is specific for this cytokine. Most interestingly, this effect increases with BMI of the adipocyte donor, indicating that adipocytes from more overweight/obese individuals suppress IL-12p40 more than from lean individuals [41]. The biological effect of this inhibition remains to be determined, as both pro- and anti-inflammatory functions have been assigned to IL-12p40 (reviewed in [63]). Scarce reports about its association with OA would suggest a pro-inflammatory function indicated by increased levels of this cytokine in OA [64,65]; however, this hypothesis needs further research. In summary, the data presented above indicate a crosstalk between IFP and neighboring tissues and support a possible role for this tissue in OA pathology.

Dual role of infrapatellar fat pad in the osteoarthritis knee

Assessing the role the IFP plays in the knee joint is difficult for several reasons. The most important is the difficulty in accessing IFP by arthroscopy, which precludes acquisition of invaluable information regarding composition, physiology, and pathology-driven changes in this tissue. A direct consequence of this is also the limited availability of information regarding the IFP in healthy

Table 1 The dual role of infrapatellar fat pad in the joint

Evidence	Reference
<i>Evidence for a protective role of IFP in the knee</i>	
IFP is preserved even under extreme emaciation conditions.	[2]
Downregulation of NO production, glycosaminoglycan release, and MMP1 expression in cartilage by FCM from IFP	[43]
Presence of specialized pro-resolving lipid mediators and their precursors in ACM/FCM from IFP	[36,37]
Presence of MSCs and macrophages with anti-inflammatory characteristics in IFP	[29,43,54]
<i>Evidence for an inflammatory role of IFP in the knee</i>	
IFP inflammation as observed on MRI is associated with knee pain	[29]
Increased pro-inflammatory cytokine secretion by IFP is correlated with BMI	[53]
Increased fibrosis by synoviocytes under influence of FCM	[24]
Increased cytokine production and proliferation of Th1 cells under influence of ACM from IFP	[51]
Increased collagen release and MMP1 and MMP13 expression	[29]

ACM, adipocyte-conditioned medium; BMI, body mass index; FCM, fat-conditioned media; IFP, infrapatellar fat pad; MMP, matrix metalloproteinase; MRI, magnetic resonance imaging; MSC, mesenchymal stem cell; NO, nitric oxide; Th, T helper.

individuals, the available data being obtained mostly from post-mortem tissues that do not necessarily reflect the healthy situation. Some studies have investigated the effects of the removal of IFP during arthroplasty for different indications, such as OA and rheumatoid arthritis (reviewed in [66]). These data would suggest that removal of IFP during total knee replacement surgeries in OA would have no effect of pain and knee function. However, these data should be carefully interpreted, as the number of studies and patients in these studies is very limited. Apart from this, some information has also been gained with non-invasive techniques, such as MRI or ultrasound. These can detect inflammatory changes in this tissue but do not offer any information about cellular and molecular mechanisms involved in the inflammatory events. The main characteristics of IFP and its known interactions with other joint tissues are graphically summarized in Figure 1. In Table 1, we summarize the evidence supporting a protective or an inflammatory role of IFP in OA, with the intent of offering a basis for future research and for a better understanding of this still elusive adipose tissue.

Conclusions

Several publications have aimed at characterizing IFP at both the cellular and the molecular level. The data summarized here indicate that IFP could have both protective and disease-enhancing effects in OA. Additional information on how IFP in patients with OA compares with IFP in healthy individuals and whether its surgical removal would be beneficial for the clinical disease could give invaluable insight into its role in the disease process. Although future studies are clearly necessary for our understanding of IFP biology, it is clear that this tissue is an active component of the joint that can modulate and influence neighboring tissues.

Abbreviations

ACM: Adipocyte-conditioned medium; BMI: Body mass index; FCM: Fat-conditioned media; IFN: Interferon; IFP: Infrapatellar fat pad; IL: Interleukin; MMP: Matrix metalloproteinase; MRI: Magnetic resonance imaging; MSC: Mesenchymal stem cell; NK: Natural killer; NO: Nitric oxide; OA: Osteoarthritis; PG: Prostaglandin; PPAR: Peroxisome proliferator-activated receptor; sc: Subcutaneous; Th: T helper; TNF α : Tumor necrosis factor-alpha.

Competing interests

The authors declare that they have no competing interests.

Acknowledgments

The authors would like to thank Anja de Jong for help with graphical illustrations and René Toes for carefully reading the manuscript. This work was financially supported by a grant obtained from Top Institute Pharma, Grant T1-213-1 (Generation of models, mechanisms and markers for stratification of osteoarthritis patients) (MK), and Grant T1-601 (AI-F).

References

1. Saddik D, McNally EG, Richardson M: **MRI of Hoffa's fat pad.** *Skeletal Radiol* 2004, **33**:433-444.
2. Smillie IS: *Diseases of the Knee Joint.* London: Churchill Livingstone; 1980.
3. Clockaerts S, Bastiaansen-Jenniskens YM, Runhaar J, Van Osch GJ, Van Offel JF, Verhaar JA, De Clerck LS, Somville J: **The infrapatellar fat pad should be considered as an active osteoarthritic joint tissue: a narrative review.** *Osteoarthritis Cartilage* 2010, **18**:876-882.
4. Hoffa A: **Influence of adipose tissue with regard to the pathology of the knee joint.** *JAMA* 1904, **43**:795-796.
5. Jacobson JA, Lenchik L, Ruhoy MK, Schweitzer ME, Resnick D: **MR imaging of the infrapatellar fat pad of Hoffa.** *Radiographics* 1997, **17**:675-691.
6. Dye SF, Vaupel GL, Dye CC: **Conscious neurosensory mapping of the internal structures of the human knee without intraarticular anesthesia.** *Am J Sports Med* 1998, **26**:773-777.
7. Bennell K, Hodges P, Mellor R, Bexander C, Souvlis T: **The nature of anterior knee pain following injection of hypertonic saline into the infrapatellar fat pad.** *J Orthop Res* 2004, **22**:116-121.
8. Schweitzer ME, Falk A, Pathria M, Brahme S, Hodler J, Resnick D: **MR imaging of the knee: can changes in the intracapsular fat pads be used as a sign of synovial proliferation in the presence of an effusion?** *AJR Am J Roentgenol* 1993, **160**:823-826.
9. Hill CL, Gale DG, Chaisson CE, Skinner K, Kazis L, Gale ME, Felson DT: **Knee effusions, popliteal cysts, and synovial thickening: association with knee pain in osteoarthritis.** *J Rheumatol* 2001, **28**:1330-1337.
10. Hill CL, Hunter DJ, Niu J, Clancy M, Guermazi A, Genant H, Gale D, Grainger A, Conaghan P, Felson DT: **Synovitis detected on magnetic resonance imaging and its relation to pain and cartilage loss in knee osteoarthritis.** *Ann Rheum Dis* 2007, **66**:1599-1603.
11. Roemer FW, Zhang Y, Niu J, Lynch JA, Crema MD, Marra MD, Nevitt MC, Felson DT, Hughes LB, El-Khoury GY, Englund M, Guermazi A, Multicenter Osteoarthritis Study Investigators: **Tibiofemoral joint osteoarthritis: risk factors for MR-depicted fast cartilage loss over a 30-month period in the multicenter osteoarthritis study.** *Radiology* 2009, **252**:772-780.
12. Hayashi D, Roemer FW, Dhina Z, Kwok CK, Hannon MJ, Moore C, Guermazi A: **Longitudinal assessment of cyst-like lesions of the knee and their relation to radiographic osteoarthritis and MRI-detected effusion and synovitis in patients with knee pain.** *Arthritis Res Ther* 2010, **12**:R172.
13. Ai F, Yu C, Zhang W, Morelli JN, Kacher D, Li X: **MR imaging of knee osteoarthritis and correlation of findings with reported patient pain.** *J Huazhong Univ Sci Technolog Med Sci* 2010, **30**:248-254.
14. Zhang Y, Nevitt M, Niu J, Lewis C, Torner J, Guermazi A, Roemer F, McCulloch C, Felson DT: **Fluctuation of knee pain and changes in bone marrow lesions, effusions, and synovitis on magnetic resonance imaging.** *Arthritis Rheum* 2011, **63**:691-699.
15. Roemer FW, Kwok CK, Hannon MJ, Green SM, Jakicic JM, Boudreau R, Crema MD, Moore CE, Guermazi A: **Risk factors for magnetic resonance imaging-detected patellofemoral and tibiofemoral cartilage loss during a six-month period: the joints on glucosamine study.** *Arthritis Rheum* 2012, **64**:1888-1898.
16. Hunter DJ, Lo GH, Gale D, Grainger AJ, Guermazi A, Conaghan PG: **The reliability of a new scoring system for knee osteoarthritis MRI and the validity of bone marrow lesion assessment: BLOKS (Boston Leeds Osteoarthritis Knee Score).** *Ann Rheum Dis* 2008, **67**:206-211.
17. Roemer FW, Guermazi A, Zhang Y, Yang M, Hunter DJ, Crema MD, Bohndorf K: **Hoffa's Fat Pad: evaluation on unenhanced MR images as a measure of patellofemoral synovitis in osteoarthritis.** *AJR Am J Roentgenol* 2009, **192**:1696-1700.
18. Subhawong TK, Eng J, Carrino JA, Chhabra A: **Superolateral Hoffa's fat pad edema: association with patellofemoral maltracking and impingement.** *AJR Am J Roentgenol* 2010, **195**:1367-1373.
19. Jibri Z, Martin D, Mansour R, Kamath S: **The association of infrapatellar fat pad oedema with patellar maltracking: a case-control study.** *Skeletal Radiol* 2012, **41**:925-931.
20. Loeuille D, Sauliere N, Champigneulle J, Rat AC, Blum A, Chary-Valckenaere I: **Comparing non-enhanced and enhanced sequences in the assessment of effusion and synovitis in knee OA: associations with clinical, macroscopic and microscopic features.** *Osteoarthritis Cartilage* 2011, **19**:1433-1439.
21. de Lange-Brokaar BJE, Ioan-Facsinay A, Yusuf E, Visser AW, Kroon HM, van Osch GJVM, Zuurmond A-M, Stojanovic-Susulic V, Bloem JL, Nelissen RGHH, Huizinga TWJ, Kloppenburg M: **Different patterns of synovitis as seen on**

- CE-MRI in patients with knee osteoarthritis. *Osteoarthritis Cartilage* 2013, **21**(suppl):S16.
22. Loeuille D, Rat AC, Goebel JC, Champigneulle J, Blum A, Netter P, Gillet P, Chary-Valckenaere I: **Magnetic resonance imaging in osteoarthritis: which method best reflects synovial membrane inflammation? Correlations with clinical, macroscopic and microscopic features.** *Osteoarthritis Cartilage* 2009, **17**:1186–1192.
 23. Crema MD, Felson DT, Roemer FW, Niu J, Marra MD, Zhang Y, Lynch JA, El-Khoury GY, Lewis CE, Guermazi A: **Peripatellar synovitis: comparison between non-contrast-enhanced and contrast-enhanced MRI and association with pain. The MOST study.** *Osteoarthritis Cartilage* 2013, **21**:413–418.
 24. Roemer FW, Guermazi A, Felson DT, Niu J, Nevitt MC, Crema MD, Lynch JA, Lewis CE, Torner J, Zhang Y: **Presence of MRI-detected joint effusion and synovitis increases the risk of cartilage loss in knees without osteoarthritis at 30-month follow-up: the MOST study.** *Ann Rheum Dis* 2011, **70**:1804–1809.
 25. Vahlensieck M, Linneborn G, Schild H, Schmidt HM: **Hoffa's recess: incidence, morphology and differential diagnosis of the globular-shaped cleft in the infrapatellar fat pad of the knee on MRI and cadaver dissections.** *Eur Radiol* 2002, **12**:90–93.
 26. Chuckpaiwong B, Charles HC, Kraus VB, Guilak F, Nunley JA: **Age-associated increases in the size of the infrapatellar fat pad in knee osteoarthritis as measured by 3 T MRI.** *J Orthop Res* 2010, **28**:1149–1154.
 27. Ioan-Facsinay A, Kwekkeboom JC, Westhoff S, Giera M, Rombouts Y, van Harmelen V, Huizinga TW, Deelder A, Kloppenburg M, Toes RE: **Adipocyte-derived lipids modulate CD4(+) T-cell function.** *Eur J Immunol* 2013, **43**:1578–1587.
 28. Odegaard JI, Chawla A: **Pleiotropic actions of insulin resistance and inflammation in metabolic homeostasis.** *Science* 2013, **339**:172–177.
 29. Kim CS, Lee SC, Kim YM, Kim BS, Choi HS, Kwon BS, Kawada T, Yu R: **Visceral fat accumulation induced by a high-fat diet causes the atrophy of mesenteric lymph nodes in obese mice.** *Obesity (Silver Spring)* 2008, **16**:1261–1269.
 30. Ushiyama T, Chano T, Inoue K, Matsusue Y: **Cytokine production in the infrapatellar fat pad: another source of cytokines in knee synovial fluids.** *Ann Rheum Dis* 2003, **62**:108–112.
 31. Distel E, Cadoudal T, Durant S, Poignard A, Chevalier X, Benelli C: **The infrapatellar fat pad in knee osteoarthritis: an important source of interleukin-6 and its soluble receptor.** *Arthritis Rheum* 2009, **60**:3374–3377.
 32. Klein-Wieringa IR, Kloppenburg M, Bastiaansen-Jenniskens YM, Yusuf E, Kwekkeboom JC, El-Bannoudi H, Nelissen RG, Zuurmond A, Stojanovic-Susulic V, Van Osch GJ, Toes RE, Ioan-Facsinay A: **The infrapatellar fat pad of patients with osteoarthritis has an inflammatory phenotype.** *Ann Rheum Dis* 2011, **70**:851–857.
 33. Presle N, Pottier P, Dumond H, Guillaume C, Lapique F, Pallu S, Mainard D, Netter P, Terlain B: **Differential distribution of adipokines between serum and synovial fluid in patients with osteoarthritis. Contribution of joint tissues to their articular production.** *Osteoarthritis Cartilage* 2006, **14**:690–695.
 34. Chen WP, Bao JP, Feng J, Hu PF, Shi ZL, Wu LD: **Increased serum concentrations of visfatin and its production by different joint tissues in patients with osteoarthritis.** *Clin Chem Lab Med* 2010, **48**:1141–1145.
 35. Gandhi R, Takahashi M, Virtanen C, Syed K, Davey JR, Mahomed NN: **Microarray analysis of the infrapatellar fat pad in knee osteoarthritis: relationship with joint inflammation.** *J Rheumatol* 2011, **38**:1966–1972.
 36. Shaikh SR, Jolly CA, Chapkin RS: **n-3 Polyunsaturated fatty acids exert immunomodulatory effects on lymphocytes by targeting plasma membrane molecular organization.** *Mol Aspects Med* 2012, **33**:46–54.
 37. Wen H, Gris D, Lei Y, Jha S, Zhang L, Huang MT, Brickey WJ, Ting JP: **Fatty acid-induced NLRP3-ASC inflammasome activation interferes with insulin signaling.** *Nat Immunol* 2011, **12**:408–415.
 38. Schmitz G, Ecker J: **The opposing effects of n-3 and n-6 fatty acids.** *Prog Lipid Res* 2008, **47**:147–155.
 39. Cascio G, Schiera G, Di Liegro I: **Dietary fatty acids in metabolic syndrome, diabetes and cardiovascular diseases.** *Curr Diabetes Rev* 2012, **8**:2–17.
 40. Serhan CN: **The resolution of inflammation: the devil in the flask and in the details.** *FASEB J* 2011, **25**:1441–1448.
 41. Klein-Wieringa IR, Andersen SN, Kwekkeboom JC, Giera M, de Lange-Brokaar BJ, van Osch GJ, Zuurmond AM, Stojanovic-Susulic V, Nelissen RG, Pijl H, Huizinga TW, Kloppenburg M, Toes RE, Ioan-Facsinay A: **Adipocytes modulate the phenotype of human macrophages through secreted lipids.** *J Immunol* 2013, **191**:1356–1363.
 42. Gierman LM, Wopereis S, van El B, Verheij ER, der Vat BJ W-v, Bastiaansen-Jenniskens YM, van Osch GJ, Kloppenburg M, Stojanovic-Susulic V, Huizinga TW, Zuurmond AM: **Metabolic profiling reveals differences in concentrations of oxylipins and fatty acids secreted by the infrapatellar fat pad of end-stage osteoarthritis and normal donors.** *Arthritis Rheum* 2013, **65**:2606–2614.
 43. Caspar-Bauguil S, Cousin B, Galinier A, Segafredo C, Nibbelink M, André M, Casteilla L, Pénicaud L: **Adipose tissues as an ancestral immune organ: site-specific change in obesity.** *FEBS Lett* 2005, **579**:3487–3492.
 44. Mathis D: **Immunological goings-on in visceral adipose tissue.** *Cell Metab* 2013, **17**:851–859.
 45. Zeyda M, Farmer D, Todoric J, Aszmann O, Speiser M, Györi G, Zlabinger GJ, Stulnig TM: **Human adipose tissue macrophages are of an anti-inflammatory phenotype but capable of excessive pro-inflammatory mediator production.** *Int J Obes (Lond)* 2007, **31**:1420–1428.
 46. Curat CA, Miranville A, Sengenès C, Diehl M, Tonus C, Busse R, Bouloumié A: **From blood monocytes to adipose tissue-resident macrophages: induction of diapedesis by human mature adipocytes.** *Diabetes* 2004, **53**:1285–1292.
 47. Duffaut C, Zakaroff-Girard A, Bourlier V, Decaunes P, Maumus M, Chiotasso P, Sengenès C, Lafontan M, Galitzky J, Bouloumié A: **Interplay between human adipocytes and T lymphocytes in obesity: CCL20 as an adipochemokine and T lymphocytes as lipogenic modulators.** *Arterioscler Thromb Vasc Biol* 2009, **29**:1608–1614.
 48. Bastiaansen-Jenniskens YM, Clockaerts S, Feijt C, Zuurmond AM, Stojanovic-Susulic V, Bridts C, de Clerck L, DeGroot J, Verhaar JA, Kloppenburg M, van Osch GJ: **Infrapatellar fat pad of patients with end-stage osteoarthritis inhibits catabolic mediators in cartilage.** *Ann Rheum Dis* 2012, **71**:288–294.
 49. Chanda D, Kumar S, Ponnazhagan S: **Therapeutic potential of adult bone marrow-derived mesenchymal stem cells in diseases of the skeleton.** *J Cell Biochem* 2010, **111**:249–257.
 50. Young HE, Steele TA, Bray RA, Hudson J, Floyd JA, Hawkins K, Thomas K, Austin T, Edwards C, Cuzzourt J, Duenzl M, Lucas PA, Black AC Jr: **Human reserve pluripotent mesenchymal stem cells are present in the connective tissues of skeletal muscle and dermis derived from fetal, adult, and geriatric donors.** *Anat Rec* 2001, **264**:51–62.
 51. Strioga M, Viswanathan S, Darinskas A, Slaby O, Michalek J: **Same or not the same? Comparison of adipose tissue-derived versus bone marrow-derived mesenchymal stem and stromal cells.** *Stem Cells Dev* 2012, **21**:2724–2752.
 52. Wickham MQ, Erickson GR, Gimble JM, Vail TP, Guilak F: **Multipotent stromal cells derived from the infrapatellar fat pad of the knee.** *Clin Orthop Relat Res* 2003, **412**:196–212.
 53. Dragoo JL, Samimi B, Zhu M, Hame SL, Thomas BJ, Lieberman JR, Hedrick MH, Benham P: **Tissue-engineered cartilage and bone using stem cells from human infrapatellar fat pads.** *J Bone Joint Surg Br* 2003, **85**:740–747.
 54. Alegre-Aguaron E, Desportes P, Garcia-Alvarez F, Castiella T, Larrad L, Martinez-Lorenzo MJ: **Differences in surface marker expression and chondrogenic potential among various tissue-derived mesenchymal cells from elderly patients with osteoarthritis.** *Cells Tissues Organs* 2012, **196**:231–240.
 55. English A, Jones EA, Corscadden D, Henshaw K, Chapman T, Emery P, McGonagle D: **A comparative assessment of cartilage and joint fat pad as a potential source of cells for autologous therapy development in knee osteoarthritis.** *Rheumatology (Oxford)* 2007, **46**:1676–1683.
 56. Khan WS, Adesida AB, Hardingham TE: **Hypoxic conditions increase hypoxia-inducible transcription factor 2alpha and enhance chondrogenesis in stem cells from the infrapatellar fat pad of osteoarthritis patients.** *Arthritis Res Ther* 2007, **9**:R55.
 57. Hui W, Litherland GJ, Elias MS, Kitson GI, Cawston TE, Rowan AD, Young DA: **Leptin produced by joint white adipose tissue induces cartilage degradation via upregulation and activation of matrix metalloproteinases.** *Ann Rheum Dis* 2012, **71**:455–462.
 58. Bastiaansen-Jenniskens YM, Wei W, Feijt C, Waarsing JH, Verhaar JA, Zuurmond AM, Hanemaaijer R, Stoop R, van Osch GJ: **Infrapatellar fat pad of OA patients stimulates fibrotic processes in cultured synoviocytes; a possible role for prostaglandin F.** *Arthritis Rheum* 2013, **65**:2070–2080.
 59. Clockaerts S, Bastiaansen-Jenniskens YM, Feijt C, De Clerck L, Verhaar JA, Zuurmond AM, Stojanovic-Susulic V, Somville J, Kloppenburg M, van Osch GJ: **Cytokine production by infrapatellar fat pad can be stimulated by interleukin 1beta and inhibited by peroxisome proliferator activated receptor alpha agonist.** *Ann Rheum Dis* 2012, **71**:1012–1018.

60. Manferdini C, Maumus M, Gabusi E, Piacentini A, Filardo G, Peyrafitte JA, Jorgensen C, Bourin P, Fleury-Cappellesso S, Facchini A, Noël D, Lisignoli G: **Adipose-derived mesenchymal stem cells exert antiinflammatory effects on chondrocytes and synoviocytes from osteoarthritis patients through prostaglandin E2.** *Arthritis Rheum* 2013, **65**:1271–1281.
61. Blaber SP, Webster RA, Hill CJ, Breen EJ, Kuah D, Vesey G, Herbert BR: **Analysis of *in vitro* secretion profiles from adipose-derived cell populations.** *J Transl Med* 2012, **10**:172.
62. de Lange-Brokaar BJ, Ioan-Facsinay A, van Osch GJ, Zuurmond AM, Schoones J, Toes RE, Huizinga TW, Kloppenburg M: **Synovial inflammation, immune cells and their cytokines in osteoarthritis: a review.** *Osteoarthritis Cartilage* 2012, **20**:1484–1499.
63. Cooper AM, Khader SA: **IL-12p40: an inherently agonistic cytokine.** *Trends Immunol* 2007, **28**:33–38.
64. Huebner JL, Kraus VB: **Assessment of the utility of biomarkers of osteoarthritis in the guinea pig.** *Osteoarthritis Cartilage* 2006, **14**:923–930.
65. Vernal R, Velasquez E, Gamonal J, Garcia-Sanz JA, Silva A, Sanz M: **Expression of proinflammatory cytokines in osteoarthritis of the temporomandibular joint.** *Arch Oral Biol* 2008, **53**:910–915.
66. Van Beeck A, Clockaerts S, Somville J, Van Heeswijk JH, Van Glabbeek F, Bos PK, Reijman M: **Does infrapatellar fat pad resection in total knee arthroplasty impair clinical outcome? A systematic review.** *Knee* 2013, **20**:226–231.

10.1186/ar4422

Cite this article as: Ioan-Facsinay and Kloppenburg: **An emerging player in knee osteoarthritis: the infrapatellar fat pad.** *Arthritis Research & Therapy* 2013, **15**:225